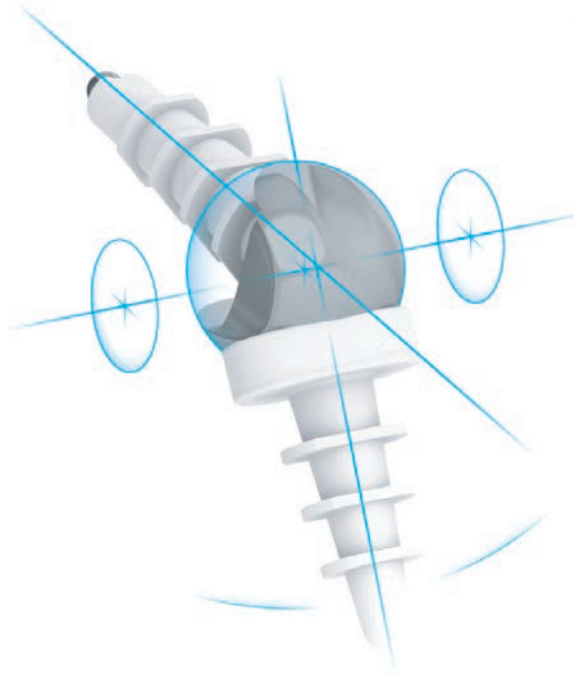

# TMPR™

## Total Metacarpophalangeal Replacement

Clinical Data Summary

**Natural Function**

Forever **Active**

## Contents

Section 1   <i>Summary Overview of Clinical Data</i>	3
Section 2   <i>Key TMPR™ Literature</i>	5
Section 3   <i>References</i>	6

Manufactured by

Mat**Ortho** Limited | 13 Mole Business Park | Randalls Road  
Leatherhead | Surrey | KT22 7BA | United Kingdom

T: +44 (0)1372 224 200 | [info@MatOrtho.com](mailto:info@MatOrtho.com)

For more information visit: [www.MatOrtho.com](http://www.MatOrtho.com)

© Mat**Ortho** Limited 2015

All rights reserved. No part of this publication may be reproduced or transmitted in any form or by any means, electronic or mechanical, including photocopy, recording or any information storage and retrieval system

# 1 Summary overview of clinical data

## Treatments for end-stage MCP joint arthritis

The metacarpophalangeal (MCP) joint is the key joint for finger function [1]. Arthritis of the MCP joint can result in considerable disability and pain [2], leading to impairment of overall hand function and severe impact on one's care for normal personal needs, daily activities and work [1].

Arthroplasty is the most common treatment option for end-stage arthritis of the MCP joint. Constrained silicone joint replacements remain the most commonly used implants, with rheumatoid arthritis being the most common indication [2]. Silastic spacers work well in joints with extensive soft tissue damage and poor bone stock, and can correct deformity, improve appearance and provide pain relief [1]. However, where the aim is to restore function in an otherwise strong hand, silastic joints severely compromise joint biomechanics and high rates of complications can occur, including device fracture, bone shortening and osseous erosions [3].

With the need for more durable implants with a lesser host-bone reaction [3], a non-constrained ball-and-socket design was developed with a pyrolytic carbon coating. Pyrocarbon was developed in the 1960s and became the standard material for heart valves. It gained an excellent track record for durability and biocompatibility. When used for the MCP and proximal interphalangeal (PIP) joints, it was also believed that osseointegration would occur [4]. However this has not been shown with in vivo testing [5] or in practice, with radiographic abnormality [6] and subsidence [7] common, despite it not necessarily leading to revision [6,7]. Subluxation, implant fracture and joint stiffness have also been described [7].

## Clinically relevant design features of the TMPR™

With a goal of restoring long-term strong, pain-free function, MCP arthroplasty must take into account all of the following factors: range of motion, stability, tendon moment arms, fixation, ease of implantation, biocompatibility, wear and strength characteristics and soft tissue construction [8]. The TMPR™ was developed in 1994 with these factors in mind.

The TMPR™ is manufactured from materials that are widely and successfully used in joint replacement: it features a stemmed cobalt-chromium (CoCr) metacarpal component articulating with an ultra-high molecular weight polyethylene (UHMWPE) proximal phalangeal component. The bearing interface is a fully conforming spherical design conducive to low wear. Stability is provided by: the congruent bearing; intraoperative consideration for the ligaments; and reproduction of the cam effect observed in the normal MCP, associated with tightening of the ligaments during flexion [9]. The cam effect results from a centre of rotation offset palmarwards from the midline of the canal [10] and it is important that that is not altered significantly [11]. The TMPR™ achieves this with an offset spherical bearing. Range of motion is otherwise unrestricted in terms of range of flexion, extension, abduction, rotation or distraction at the joint surface.

The anatomical geometry of the TMPR™ was determined from data for a spectrum of adult patients. Further anatomical and soft tissue considerations include flared polished panels to protect the collateral ligaments, a dorsal groove for the extensor tendon and shaping of the phalangeal component for the extensor hood.

Ease of implantation is facilitated with a fully jigged operative procedure that includes templating, fully guided surface and stem preparation, tools for functional assessment and an appropriate size range for the population with modular options to best match bearing and fixation requirements.

Good fixation is central to the TMPR™ design and is achieved with uncemented finned polyethylene plugs. The anatomically-shaped fins flex during insertion and are sufficiently strong to spring back to engage the endocortical surface for immediate post operative fixation. The modular design of the metacarpal replacement permits motion at the metal-polyethylene stem interface and so shields the fixation interface from these stresses.

## Clinical outcomes

The TMPR™ has been in clinical use since 1994 with over 80 implantations recorded to date. The following data was reported by Harris and Dias [12] on a series of 13 joints implanted in 7 patients with degenerative arthritis and one with rheumatoid arthritis and early ulnar drift. Mean age at surgery was 60.5 years (range 48 to 69) and patients were followed up at 3 and 5 years.

## Operative technique

Harris and Dias reported no technical problems other than one metacarpal component inserted in slight extension with no functional or radiographic effect, and difficulty inserting the phalangeal plug when impactors rather than rasps were used [12]. The instruments now include rasps as standard.

Difficulties with preserving tendon and ligament balance have been described elsewhere [8], however this was not found for the TMPR™ with alignment and joint spacing guided by the instruments.

## Pain relief

Using a visual analogue scale (VAS), Harris and Dias reported an improvement from 94% (SD, 9) before surgery to mean 6% (SD, 12.4) at 3 years and 2% (SD, 6) five years after surgery [12].

## Range of motion (ROM)

Most daily activities require an arc in the range of about 10° to 70° of flexion [13]. Harris and Dias reported an improvement in arc of motion from 23°-50° flexion to a satisfactory 10°-70° flexion: a mean improvement in ROM from 27° (SD, 9°) to 60° (SD, 13°) [12].

## Strength

With the anatomical design and reproduction of the joint centre of rotation, Harris and Dias found that pinch and grip strength were preserved at 3 and 5 years follow-up [12].

## Fixation

The finned UHMWPE fixation has been used successfully since the 1970s with good results [14]. A similar radiographic appearance of dense bone surrounding the device described by Blaha et al. [13] can be observed for the TMPR™ [Fig. 1]. Harris and Dias reported 12 of the 13 joints had showed no change in position or angulation of the metacarpal component at 5 years [12]. One metacarpal component had settled by 2mm after 6.8 years but with no evidence of loosening.

## Wear

Harris and Dias found no signs of wear at 5 years, but noted that some wear is inevitable in the long term [12].

## Patient evaluation measures

Patient's own VAS scale assessments were mean 6/7 for flexion, extension and movement at 3 and 5 years, where 7 is normal. Similarly, patient evaluation measure (PEM) scores improved from mean 77% (63-91) pre operatively to mean 9% (3-17) and 9% (2-17) 3 and 5 years post operatively [12].

## Survivorship

Harris and Dias reported only one patient having any complication [12]. A joint had become infected following intraoperative tendon damage and a slow healing wound. The joint was revised, demonstrating it could be easily removed without gross loss of bone stock, and a further TMPR™ was implanted with fins removed and bedded in cement, resulting in pain-free active movement.

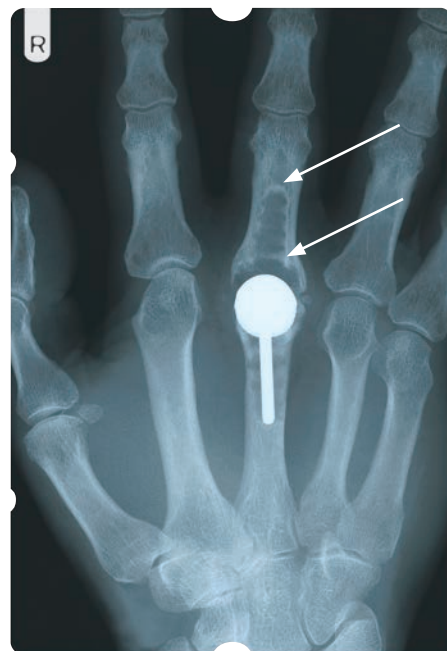


Figure 1 Dense bone surrounding the fixation observed radiologically [14].

## Summary

The TMPR™ aims to replicate an anatomical MCP joint and offer a restored range of motion and near-normal function to patients. Data shows that the device:

- Offers good pain relief;
- Improves range of active movement to that required for activities of daily living;
- Enables the achievement of a strong, stable grip;
- Is reported by patients to restore near normal function;
- Has minimal reported intraoperative and postoperative complications.

Pain, range of motion and patient perceptions of function are excellent with this device. All values reported are superior to previous reports [3,7,10], however the study reported primarily on treatment of degenerative arthritis and only one patient with rheumatoid arthritis.

## 2 Key TMPR™ literature

### Morphological measurements of the proximal interphalangeal joint

Harris D and Dias JJ. J Hand Surg (Br&Euro). 2003; 28B(5): 432-438

An unconstrained surface metacarpophalangeal joint replacement was developed with metal metacarpal and polyethylene phalangeal components, fixed by uncemented finned polyethylene plugs which allowed some metacarpal component motion. Clinical and radiological results in 13 joints in eight patients are presented after 5 years. One infection required revision at 3 months. There were no further complications. At final review there were no implant failures. Two of 13 joints showed lucency around the phalangeal component and one showed 2mm subsidence of the metacarpal component. No other adverse radiological features were observed. Seven patients had no pain and one had minor discomfort. Joint movement had improved from an arc of 27° to 60° and disability, assessed using the P.E.M. questionnaire, had improved from 77% to 9%.

## References

1. Swanson AB. Flexible implant arthroplasty for arthritic finger joints: rationale, technique, and results of treatment. *J Bone Joint Surg Am.* 1972; 54(3): 435-55.
2. Rizzo M. Metacarpophalangeal Joint Arthritis. *J Hand Surg (Am).* 2011; 36(2): 345–353.
3. Goldfarb CA and Stern PJ. Metacarpophalangeal joint arthroplasty in rheumatoid arthritis. A long-term assessment. *J Bone Joint Surg Am.* 2003; 85-A(10): 1869-78.
4. Watts AC. And Trail IA. Wrist and Hand Focus On: Anatomical small joint replacement in the hand. *Bone and Joint.* 2004
5. Daecke W, Veyel K, Wieloch P, Jung M, Lorenze H and Martini A-K. Osseointegration and Mechanical Stability of Pyrocarbon and Titanium Hand Implants in a Load-Bearing In Vivo Model for Small Joint Arthroplasty. *J Hand Surg (Am).* 2006; 31(1): 90-97.
6. Petscavage JM, Alice SH and Chew FS. Arthroplasty of the Hand: Radiographic Outcomes of Pyrolytic Carbon Proximal Interphalangeal and Metacarpophalangeal Joint Replacements. *Am J Roentgenol.* 2011; 197(5): 1177-81.
7. Cook SD, Beckenbaugh RD, Redondo J, Popich LS, Klawitter JJ, Linscheid RL. Long-term follow-up of pyrolytic carbon metacarpophalangeal implants. *J Bone Joint Surg Am.* 1999; 81(5): 635-48.
8. Linscheid RL. Implant arthroplasty of the hand: Retrospective and prospective considerations. *J Hand Surg (Am).* 2000; 25(5): 796–816.
9. Youm Y, Gillespie TE, Flatt AE and Sprague BL. Kinematic investigation of normal MCP joint. *J Biomech.* 1978; 11(3); 109-118.
10. Trail I.A. Arthroplasty of the Metacarpophalangeal Joint. In: *Arthroplasty of the Hand and Wrist.* 2010; Chapter 4: 83-110. Publ: Lawrenceckirk, Amadeus Press, Cleckheaton, UK.
11. Minami M, Yamazaki J, Kato S and Ishii S. Alumina ceramic prosthesis arthroplasty of the metacarpophalangeal joint in the rheumatoid hand. *J Arth.* 1988; 3(2): 157-166.
12. Harris D. and Diaz JJ. Five-year results of a new total replacement prosthesis for the finger metacarpo-phalangeal joints. *Journal of Hand Surgery (British and European Volume).* 2003; 28B (5): 432–438
13. Rand DT and Nicol AC. An instrumented glove for monitoring MCP joint motion. *Proc Inst Mech Eng – H.* 1993; 207(4): 207-210.
14. Blaha JD, Insler HP, Freeman MA, Revell PA, Todd RC. The fixation of a proximal tibial polyethylene prosthesis without cement. *J Bone Joint Surg Br.* 1982; 64(3):326-35.





Forever **Active**



MatOrtho Limited | 13 Mole Business Park | Randalls Road | Leatherhead | Surrey | KT22 7BA | United Kingdom  
T: +44 (0)1372 224 200 | info@MatOrtho.com | For more information visit: [www.MatOrtho.com](http://www.MatOrtho.com)

Part No. ML-300-194 L | issue 1